



CASE REPORT

Case Study: Disseminated intravascular coagulation at autopsy of a child with severe burns resulting in death

Muhammad Yusuf Arrozhi^{1*}, Rusyad Adi Suriyanto², Hendro Widagdo³

¹ Department of Forensic Science and Medicolegal, Faculty of Medicine, Ahmad Dahlan University, Yogyakarta, Indonesia

^{2,3} Department of Forensic Science and Medicolegal, Faculty of Medicine, Gadjah Mada University, Yogyakarta, Indonesia

² Bioanthropology and Paleoanthropology Laboratory, Faculty of Medicine, Gadjah Mada University, Yogyakarta, Indonesia

* Corresponding author, email: muhammad.arrozhi@med.uad.ac.id

ARTICLE INFO

ABSTRACT

Keywords:

DIC (Disseminated Intravascular Coagulation) forensic autopsy burns in corpses

Childhood is a time of growth and development, both intellectually and emotionally. The Indonesian Child Protection Commission has observed growing violence against children, including physical and verbal abuse, which requires special attention and handling. Physical violence can include burns, which are particularly dangerous in developing countries with high mortality rates. Severe burns can result in inhalation injury and sepsis, which can cause coagulation disorders, making it easier for Disseminated Intravascular Coagulation (DIC) to occur. This study aims to describe the coagulation function of severely burned patients, investigate the potential causes of DIC, and examine other clinical data. The study used a case study approach, analyzing a child's corpse suffering from severe burns. An autopsy was performed, and supporting examinations were conducted to determine the cause of death. The investigation of the patient's laboratory results, treatment records, corpse, and anatomical pathology revealed the presence of DIC. The autopsy of the child's corpse showed severe burns, pale colouring in the tissues under the nails, and blood clots in the epidural, left ventricle, right ventricle, and veins. The cause of death was determined to be severe burns causing multiple organ dysfunctions.

1. Introduction

Childhood is crucial for physical, intellectual, and emotional growth and development. Monitoring by the Data and Information Center of the National Commission for Children has revealed that 62% of child violence occurs close to the child. Violence is a deliberate act that leads to physical harm or psychological trauma. One of the causes of verbal violence toward children is the lack of awareness among parents about such violence. The Indonesian Commission on Child Protection (KPAI) has reported a rising trend in child abuse cases in Indonesia, with 6,006 cases reported in April 2015. This number has steadily increased yearly, with 171 cases in 2010; 2,179 cases in 2011; 3,512 cases in 2012; 4,311 cases in 2013; and 5,066 in 2014 (Setiawan, 2015).

Children, especially those under four years of age, are particularly vulnerable to burns as they may not be able to recognize potential hazards in their surroundings. In developed countries, most burns (70%) occur in young children, with boys aged 1-2 years being the most affected. Scald injuries are more prevalent than flame burns and are often caused by spilt boiling water or cooking oil. Scalds usually have a brief contact time, but the contact time increases when clothing is involved. Flame burns are more severe as they are of a higher temperature and can cause necrosis, along with two zones of venous stasis and hyperaemia. Direct tissue heating and secondary inflammation lead to significant fluid loss, up to 200 ml/m²/h (Alnababtah *et al.*, 2011). The hands and forearms were the body parts that experienced the highest frequency of injuries

<https://doi.org/10.30659/sainsmed.v14i1.30098>

(59.2%), while the thigh and head were affected by eight patients each (10.5%). Other areas that were affected included the chest (7.9%), feet (7.9%), upper arms (2.6%), and lower legs (1.3%). The majority of cases were caused by hot food or drinks (53.9%), followed by incidents involving hot ovens or fireplaces (30.3%) and open fires or firecrackers (15.8%) (Cintean *et al.*, 2023).

Out of 8,089 patients admitted to the Intensive Care Unit, who were residents of Olmsted Country, 154 patients met the criteria for Disseminated Intravascular Coagulation (DIC). The overall incidence rate of DIC per 100,000 person-years decreased from 26.2 (95% CI, 17.1-38.4) in 2004 to 18.6 (95% CI, 11.3-28.7) in 2010. The incidence rate of DIC was higher in men than women, except for the age group 18 to 39 years. The incidence rate of DIC increased with age for both genders. For men, the incidence rate of DIC per 100,000 person-years decreased from 41.6 (95% CI, 25.4-64.2) in 2004 to 21.2 (95% CI, 10.6-37.9) in 2010 ($p = 0.01$), while for women, it did not change significantly ($p = 0.79$). There was no significant change in the case fatality rate during the study period (Singh *et al.*, 2013).

Burns is a significant problem in developing countries, with over 2 million cases reported annually in India alone. The mortality rate from burns is higher in developing countries compared to developed countries; for instance, in Nepal, there are approximately 1,700 deaths per year for every 20 million people, which results in a mortality rate 17 times higher than in the U.K. The high mortality rate can be attributed to various factors, including Sepsis, inhalation trauma, and multiorgan failure (Hettiaratchy & Dziewulski, 2004).

Patients who experience severe trauma and burns often consume large amounts of coagulation factors and other regulatory proteins. However, severe burns can result in imbalances in the coagulation, fibrinolytic, and inflammatory systems. Inhalation injury and sepsis worsen the recovery prognosis and increase the risk of

respiratory failure, septic shock, and DIC. Research on coagulation in severe burns remains limited (Zhang, Ba, Li, *et al.*, 2022).

Therefore, this study aims to describe the coagulation function in patients with severe burns, investigate the potential causes of its occurrence, and gather other relevant clinical data.

2. Literature Review

2.1. Burns

Burns are defined as physical trauma caused by high temperatures, which is the most prevalent cause of heat sources to the body, including fire, heated surfaces, hot metals, hot liquids, and hot gases. Burns are a form of injury (tissue damage or loss) brought on by heat, high temperatures, electrical sources, chemicals, light, radiation, and friction. According to the depth of the afflicted skin layer, the severity of burns is classified and divided into degrees: 1 (superficial wounds), 2A (partial thickness), 2B (total thickness), and 3 (full thickness +) (DiMaio & Kimberley, 2021).

Three concentric zones of tissue trauma are visible after a third-degree burn: coagulation (areas in direct contact with the heat source appear white or charcoal), stasis (tissue perfusion is visual), and hyperemia. Burns can result in immediate or delayed demise. Carbon monoxide (CO) poisoning, smoke inhalation, mechanical trauma, anoxia, and hypoxia are causes of mortality (DiMaio & Kimberley, 2021).

2.2. Disseminated Intravascular Coagulation (DIC)

According to the International Society of Thrombosis and Haemostasis (ISTH) Scientific and Standardization Committee, Disseminated Intravascular Coagulation (DIC) is a syndrome characterized by activation of the intravascular coagulation process, leading to a loss of its normal localization. This activation can damage the microvasculature, potentially

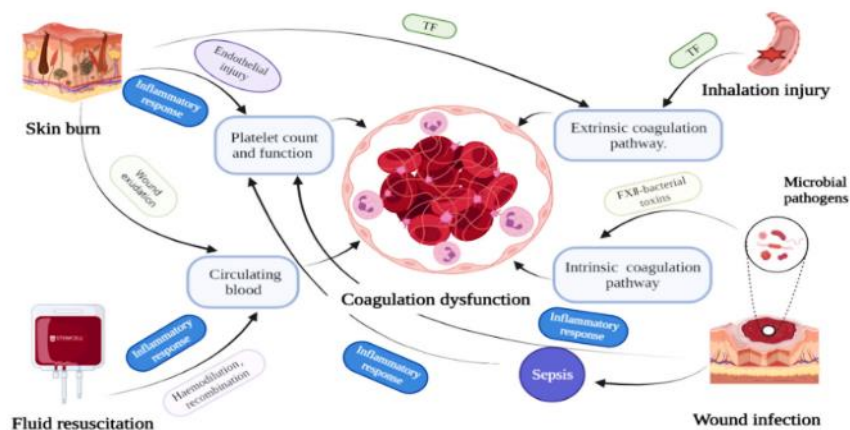


Figure 1. Correlation between inhalation injury, sepsis, fluid resuscitation, burn injury, and coagulation dysfunction. (Tissue factor) TF; (Coagulation factor XII) FXII (Zhang *et al.*, 2022).

Table 1. Diagnostic criteria for DIC (Takemitsu *et al.*, 2011)

Establish	Points	JMHW	ISTH	JAAM
Underlying disease	1	1 point	necessary	necessary
Clinical symptoms	1	bleeding*	-	SIRS 1 point
	1	organ failure		
Platelet counts ($\times 10^3/\mu\text{l}$)	1	>80 but <120*	>50 but <100	>80 but <120 #1
	2	>50 but <80*	<50	80 < #2
	3	<50*		
Fibrin-related marker	1	F.D.P. ($\mu\text{g/mL}$)	F.D.P., S.F., or D-dimer	>10 but <25
	2	>10 but <20	Moderately increased	>25
	3	>20 but <40	Markedly increased	
Fibrinogen (g/l)	1	>1 but <1.5	<1	-
	2	<1		
PT, PT ratio,	1	>1.25 but <1.67	Prolongation of P.T.	>1.2
Prolongation of PT	2	>1.67	>3 but 6<	
Diagnostic of DIC	points	≥ 7	≥ 5	≥ 4

*: 0 points with hematopoietic malignancy. #1: or a 30% reduction in the platelet count. #2: or a 50% reduction in the platelet count.

resulting in severe organ dysfunction. The intravascular activation of the coagulation process leads to the formation of thrombin and fibrin, causing small- to medium-sized vessel thrombosis, organ dysfunction, and severe bleeding. DIC can be associated with severe trauma and serious injuries (Taylor *et al.*, 2001).

2.3. DIC Pathophysiology

Mitra *et al.* (2013) retrospectively found hypercoagulability within 24 h after a burn, while Wiegele *et al.* (2019) reported that patients developed chronic hypercoagulability two weeks after a burn injury using a coagulation test at four-time points. When the pulmonary epithelium and alveolar macrophages are damaged by inhalation injury, tissue factor is released, activating the exogenous coagulation pathways and resulting in pulmonary coagulopathy. Hypoxia caused by inhalation injury can lead to local thrombosis, and sepsis can activate severe burns, which can, in turn, activate endogenous coagulation pathways and even result in DIC (Figure 1). Despite the increased risk of death, the close association between inhalation injury, burn sepsis, and coagulation in patients can exacerbate coagulation dysfunction after severe burns. Thus, additional studies are needed to understand better the association between inhalation injury, burn sepsis, and coagulation.

2.4. DIC Clinical Manifestations in Burn Patients

Some of the clinical manifestations observed in burn patients with DIC include thrombophlebitis that occurs at unusual sites, respiratory distress syndrome, kidney dysfunction characterized by a decrease in kidney function, central nervous system disorders such

as loss of consciousness and seizures, dermal infarction and skin necrosis, as well as grey discoloration of the fingertips, toes, or earlobes (Thachil, 2016).

2.5. Scoring system

The recommendations used include guidelines issued by International Society on Thrombosis Haemostasis-Scientific and Standardization Committee (ISTH-SSC), the Japanese Ministry of Health, Labor, and Welfare (JMHLW), and the Japanese Association of Acute Medicine (JAAM) (Table 1) (Takemitsu *et al.*, 2011).

2.6. Overt DIC

They were defined as a condition where the vascular endothelium, blood, and its components have lost their ability to compensate and restore homeostasis in response to injury, resulting in multiorgan dysfunction due to thrombosis and bleeding. A score of 5 or more on the DIC assessment scale constitutes overt DIC. (Table 2) (Taylor *et al.*, 2001).

2.7. Non-overt D.I.C.

It is defined as a clinical vascular injury resulting in a severe burden on the homeostatic system, temporarily preventing further inflammatory and hemostatic activation. The scoring techniques used for the diagnosis of non-overt DIC include general coagulation tests, such as Prothrombin time and Fibrin Degradation Products, and more specific but not widely available tests that indicate intravascular thrombin production, such as Thrombin-Antithrombin (TAT) complexes, and the consumption of coagulation inhibitors, such as Antithrombin (AT) and Protein C

Table 2. Diagnostic Scoring System for Overt D.I.C. (Taylor Jr., Toh, Hooth W. Keith, et al., 2001)

Variable	Overt D.I.C. by ISTH	Overt D.I.C. by KSTH	Points
Platelet count (/μL)	50,000-100,000	<100,000	1 point
	<50,000		2 point
P.T./aPTT	Prolongation of PT 3-6	Prolongation of PT >3sec or Prolongation of aPTT >5sec	1 point
	Prolongation of PT ≥6		2 point
Fibrinogen (mg/dL)	<100	<150 mg/dL	1 point
D-dimer (μg/mL)	0.5-1	Increase	1 point
	1-3		2 point
	≥3		3 point
Total	Overt DIC ≥ 5 points	Overt DIC ≥ 3 points	

ISTH: International Society on Thrombosis Haemostasis. KSTH: Korean Society on Thrombosis and Haemostasis.
PT: prothrombin time. aPTT: activated partial thromboplastin time

Table 3. Quick SOFA Score (Marik & Taeb, 2017; Putra, 2018)

Assessment	Score
Respiratory rate ≥22 breaths/min	1
Systolic blood pressure < 100 mmHg	1
Altered mental status (G.C.S. <14)	1

(PC) (Wada et al., 2013).

2.8. Quick SOFA Score

According to the Surviving Sepsis Campaign (SSC.) 2017 guidelines, the Quick SOFA (qSOFA) scoring system can immediately identify Sepsis without waiting for blood test results. This scoring system is a modification of the Sequential (Sepsis-related) Organ Failure Assessment (SOFA). qSOFA consists of only three assessment components, each with one value (Table 3). A qSOFA score of ≥2 indicates the presence of organ dysfunction. The qSOFA score is recommended for identifying patients at high risk of deterioration and predicting the length of stay for patients in both the ICU. and non-ICU settings (Marik & Taeb, 2017; Putra, 2018).

3. Case Report

According to the investigator's statement, at 2:00 pm. local time, the Temanggung Police received a report from the public about the burning of a child allegedly committed by the biological father at 1:00 p.m. It was reported that the father scolded the child for an error and poured gasoline on them before setting them on fire. The father also sustained burns while attempting to save the child by embracing them. The mother discovered the incident and sought help from

the neighbours to take the victim and the father to Temanggung Regional Hospital. The mother found the incident and sought help from the neighbours to take the victim and the father to Temanggung Regional Hospital at 1:20 p.m. Later, the victim was referred to Sardjito Central Hospital from Temanggung Regional Hospital. The victim arrived at Sardjito Central Hospital at 11:00 p.m. and was pronounced dead the next day at 4:00 a.m. After that, the victim's family reported the death to the Temanggung Police. The investigator then issued a Letter of Request for a postmortem examination to be conducted on the victim. Subsequently, an autopsy was born on the body at Sardjito Central Hospital at 11:40 a.m.

The examination of the victim, while he was still alive, revealed loss of consciousness Glasgow Coma Scale (GCS) paediatrics score (Eyes 3, Verbal 2, and Motor 5), vital signs with low blood pressure (100/60 mmHg), average heart rate (98 beats per minute), increased respiration rate (28 breaths per minute), decreased oxygen saturation (88%), and increased body temperature (38°C). The victim had 2A-degree burns all over his body and received medical treatment, including an infusion, urinary catheter, and oxygen mask (Figure 1). The laboratory examination showed increased leukocytes ($52.13 \times 10^3/\mu\text{L}$), increased erythrocytes ($6.23 \times 10^6/\mu\text{L}$), increased haemoglobin (18.1 g/dL), average Blood Ureum Nitrogen (12.60 mg/dL), increased hematocrit (55.1%), increased platelet ($808 \times 10^3/\mu\text{L}$), increased alanine transaminase (104 U/L), normal alanine aminotransferase (25 U/L), increased creatinine (1.56 mg/dL), increased random blood glucose (164 mg/dL) and decreased albumin levels (2.70 g/dL), increased PaO₂ (314 mmHg). But,

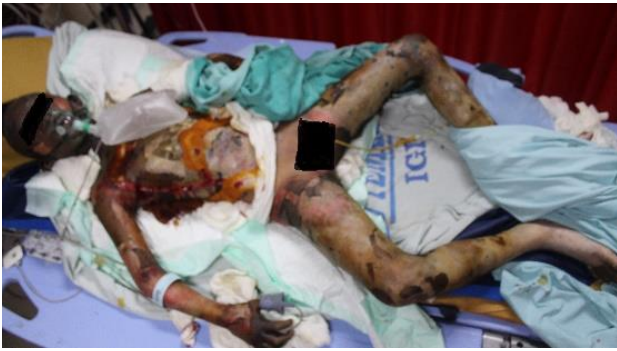

Figure 2. The patient, when being treated in the Emergency Department of Dr Sardjito Teaching Hospital

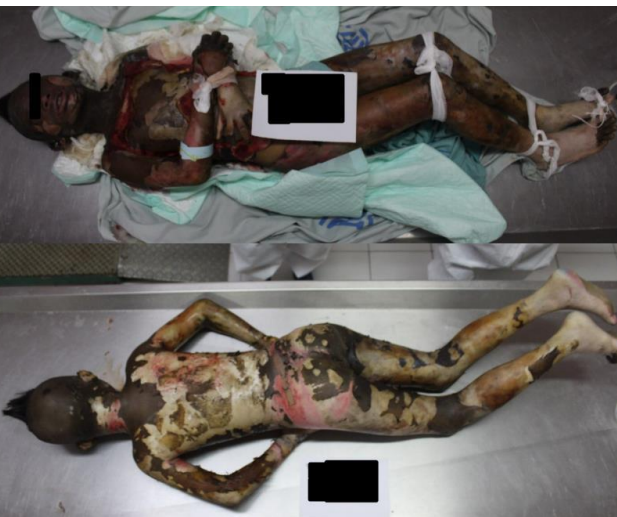

Figure 3. The corpse is seen from the front and back

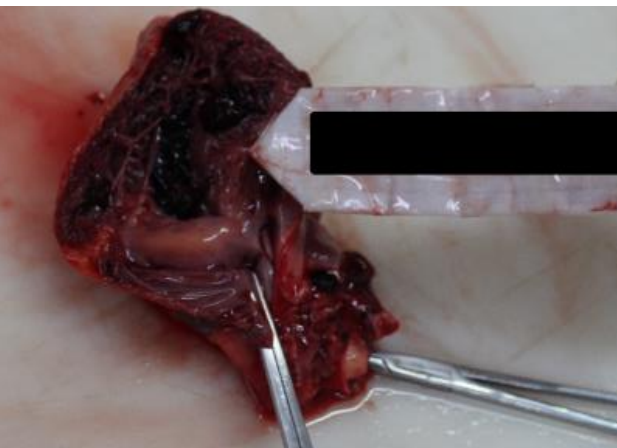


Figure 4. Blood clots in the left ventricle, right ventricle, and venous vessels

in the examination of Activated Partial Thromboplastin Time (APTT), Plasma Prothrombin Time (PPT), International Normalized Ratio (INR), Fibrinogen, and D-Dimer, the tests could not be performed because the blood sample had lyzed in the coagulation tube.

The victim's autopsy revealed a body length of 140 cm, a weight of 30.9 kg, and male sex with 28 teeth. The whole body was found to have 2A-degree burns covering 94.5% of the body. There were also signs of

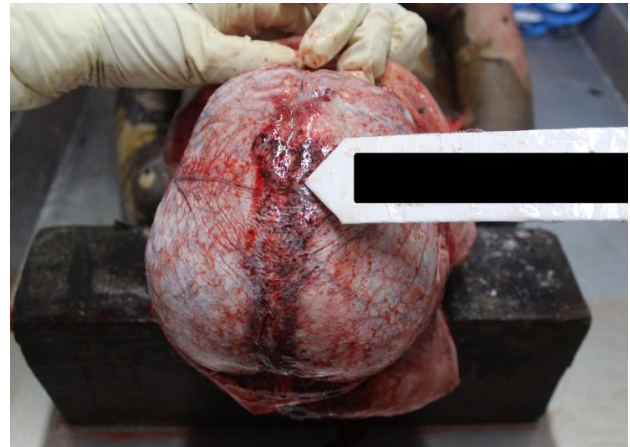


Figure 5. Blood clot in the brain's dura mater

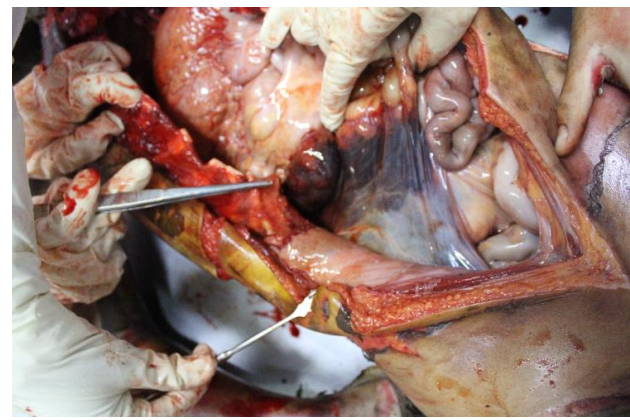


Figure 6. Blood clot in the right abdomen.

escharotomy on the chest and abdomen, with pale tissue under the nails of the toes and hands and blood coming out of the right ear canal. An escharotomy was performed on the chest and abdomen of the deceased, as shown in Figure 3.

The abnormalities found on the deceased's internal examination include no soot. There are blood clots under the brain's complex membrane (Figure 5), the veins of the heart, the left ventricle, the right ventricle (Figure 4), and the right abdomen (Figure 6).

Upon examination of the anatomical pathology, the results obtained were in the form of:

- a. Brain: within normal limits
- b. Cerebral membranes: swollen with extensive extravasation of red blood cells (Figure 7).
- c. Trachea: within normal limits
- d. Throat: within normal limits
- e. Heart: blood clots were found in the right and left chambers of the heart (Figure 8).
- f. Lungs: swollen with dilation of blood vessels and extravasation of red blood cells.
- g. Kidney: found extensive erythrocyte extravasation in fatty tissue at the edge of the right kidney; right and left kidney tissue was normal (Figure 9).
- h. Liver: within normal limits (Figure 10).

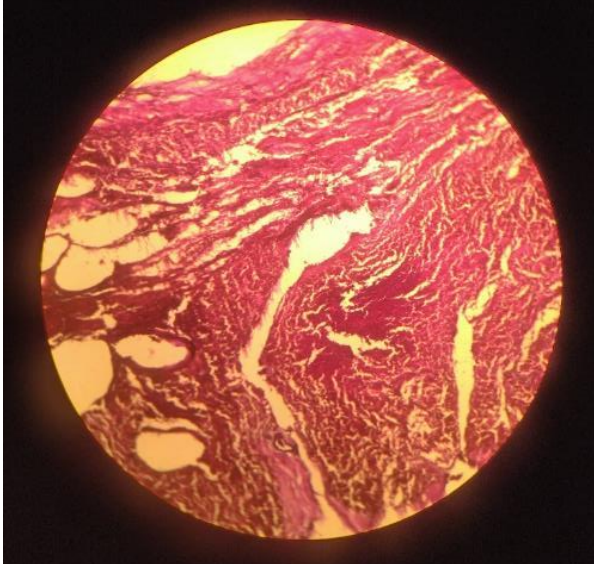


Figure 7. Dura mater with 10 X microscope magnification

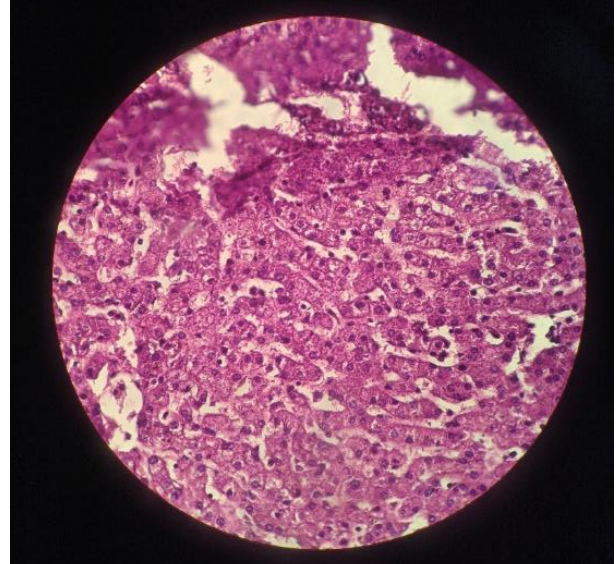


Figure 10. Liver with 40X microscope magnification

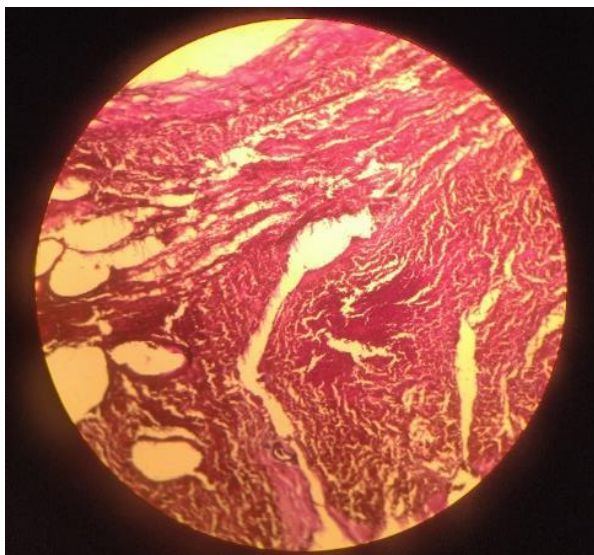


Figure 8. Right ventricle with 40 X microscope magnification

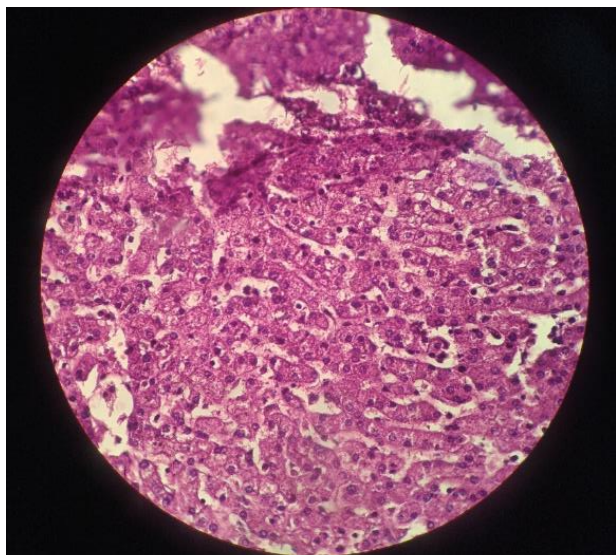


Figure 11. 2A-degree burn on the skin

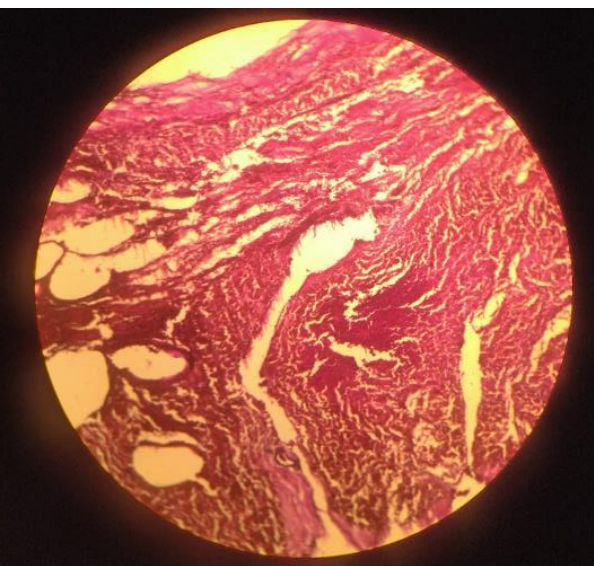


Figure 9. Right kidney with 10 X microscope magnification

- i. Skin: 2A-degree burns (superficial partial-thickness burn), characterized by partial erosion of the epidermis, partially detached from the dermis to form subepidermal bullae. The upper dermis was swollen with extravasation of erythrocytes, necrosis, and neutrophil discharge (Figure 11).

4. Discussion

The Temanggung Police received a report from the public at approximately 2:00 p.m. concerning the burning of a child allegedly committed by his biological father. Upon visiting the crime scene, witnesses were interviewed, and evidence was collected, leading to the identification of the perpetrator.

In the laboratory examination of the victim, there was insufficient data to calculate the DIC score. Because the laboratory examination of hemostasis function in

the form of PTT, APTT, D-Dimer, and Fibrinogen in a blood sample tube containing sodium citrate resulted in lysis, the results could not be obtained. However, the leukocyte count indicated that the victim was in septic shock, a significant factor in developing DIC. The initial examination of the body revealed evidence of medical intervention in the form of escharotomy or fasciotomy, which was performed to prevent respiratory distress and relieve pressure on critical structures in the extremities (such as blood vessels and nerves). This escharotomy was completed without signs of a full-thickness burn that would have caused oedema and compromised blood vessels (Zhang *et al.*, 2022).

Establishing a DIC diagnosis is difficult as no test is considered a gold standard (Wada *et al.*, 2012). Small vessel thrombi can be directly visualized during the autopsy; in many cases, patients with DIC are not suspected (Lucas, 2007). In living patients, DIC diagnosis heavily relies on nonspecific laboratory test results, nonspecific signs and symptoms, and low-sensitivity scoring systems. These factors make real-world DIC diagnosis challenging, and most existing literature may be unreliable (Dewar, 2022).

In the patient, signs of infection were found, with 3 points on the qSOFA score, a systolic blood pressure of 100 mmHg, a respiratory rate of 28 breaths per minute, and a decreased level of consciousness with a Glasgow Coma Scale (GCS) paediatrics score of Eyes 3, Verbal 2, Motor 5. Thus, the quick SOFA score was 3, indicating definite signs of sepsis. Sepsis is the most common cause of DIC, and the severity of sepsis can increase the likelihood of DIC, which worsens the clinical picture. Sepsis triggers almost all the factors that lead to DIC (Singh *et al.*, 2013). The immune response in sepsis is pro-coagulant, and there is a dysfunction of standard anticoagulant factors and fibrinolysis that usually provide protection. The septic and inflammatory state also damages the endothelium and platelets, leading to widespread and uncontrolled thrombus formation in the microvasculature, contributing to organ dysfunction and worsening the clinical picture. Eventually, the body's clotting factors are exhausted, leading to a hypo-coagulable and fibrinolytic state with clinically apparent bleeding. If DIC is diagnosed due to bleeding in this group, the process is already at an advanced stage. DIC caused by sepsis often has a poor outcome compared to DIC from other causes. The concept of "Sepsis Induced Coagulopathy" (SIC) has been proposed, which is not synonymous with DIC but may be part of a continuum, with "overt DIC" being a clinical endpoint. Diagnosis of SIC is predictive of later development of DIC, and using SIC as a pre-screening tool can enable closer monitoring or intervention for those at risk of developing DIC. A

specific SIC score for pediatric patients has not been set. Still, similar mechanisms likely hold for this population with Multiorgan Dysfunction Syndrome, and there are signs of DIC development in this patient (Iba & Levy, 2020).

The examination also showed bruising and stiffness of the body, which were difficult to assess, and there was no decomposition. This was due to a "pugilistic posture," a condition where the muscles have coagulated due to heat, causing the contraction of flexor muscle fibres (Saukko & Knight, 2016). The external examination revealed burns to almost the entire body. The 12-year-old male victim had sustained 2A-degree burns, covering 94.5% of his body, as determined using the Rules of Nines and the Wallace formula for calculating total body surface area (Moore *et al.*, 2022).

The burns were characterized as superficial partial-thickness burns, with partial erosion of the epidermis and detachment from the dermis, forming subepidermal bullae. The upper dermis was swollen and showed signs of extravasation of erythrocytes, necrosis, and neutrophil accumulation (DiMaio & Kimberley, 2021). Examination of the nails revealed that all the fingers and toes were pale, a sign of decreased blood perfusion to the tissues. This was due to the severe burns causing DIC and leading to blood clots and impaired perfusion (Thachil, 2016).

The mechanism of death resulting from a 94.5% 2A-degree burn that causes blood clotting can be explained as follows: The victim sustained high-temperature trauma antemortem, evidenced by the presence of erythema from capillary distention, vesicles containing serous fluid that showed albumin, chloride, PMN (polymorphonuclear) cells, and a reddened, inflamed base with raised papillae. The skin around the blisters was bright red or copper, a characteristic that distinguishes between postmortem and antemortem burns. Although no soot was found in the throat or respiratory tract during the autopsy, a sign of antemortem burning, the other findings indicate that the victim died from the burns (Saukko & Knight, 2016).

This case of burning a 12-year-old Mongolian male is rare and presents a challenge for physicians and forensic pathologists in determining the cause of death. The examination of burn victims often focuses on inhalation and skin trauma, but it is crucial to consider the potential for increased blood coagulation and the development of D.I.C. A complete forensic investigation, including laboratory and anatomical pathology, can help reconstruct the case and establish the cause of death. This case provides valuable references for similar issues in the future.

It is recommended that standard operating procedures be established for examining burn victims

and fluid or human tissue samples to ensure that the most appropriate therapeutic doses can be determined and more cases can be saved in the future.

5. Conclusions

The male body, with a body length of 140 cm and weighs 90 kg. There are second-degree burns covering 94.5% of the body. Blood clots are under the brain's complex membrane, in the heart's veins, the left ventricle, the right ventricle, and the right abdomen. The cause of death was severe burns, resulting in multiple organ dysfunction. The time of death cannot be estimated due to the extensive nature of the burns.

Coagulopathy is a frequent and significant complication in septic patients that leads to organ dysfunction. Progression to DIC, which carries a high mortality risk, can occur in sepsis cases. Comprehensive health monitoring, including screening, prevention, and early intervention, is necessary for all child burn victims and should be integrated into pediatric burn unit practices to achieve optimal outcomes. Additional research and autopsy investigations are required for individuals of all ages who have suffered extensive burns to assist in evaluating, preventing, diagnosing, and managing burn-induced DIC.

Acknowledgement

We would like to thank all the lecturers and colleagues at the Department of Forensic Medicine and Medicolegal at Universitas Gadjah Mada and the Faculty of Medicine at Universitas Ahmad Dahlan for their guidance and support in publishing this manuscript.

Conflict of Interest

The authors have declared no conflict of interest.

Funding

This review was conducted at no cost.

Data and Material Availability Section

The data sets collected and presented in this review are available as open-access data as cited in our references.

Author Contributions

MYA, R.A.S., and H.W. directed the discussion, collected all the data, and prepared the script. All authors participated in writing and approved the final manuscript.

Competitive Interests

The authors have stated that there is no competing interest.

Publishing Permit

Not required.

Ethics Approval and Participating Consent

Not required.

References

- Alnababtah, K.M., Davies, P., Jackson, C.A., Ashford, R.L., et al. (2011) Burn injuries among children from a region-wide paediatric burns unit. *British Journal of Nursing*. [Online] 20 (3). Available from: doi:10.12968/bjon.2011.20.3.156.
- Cintean, R., Eickhoff, A., Zieger, J., Gebhard, F., et al. (2023) Epidemiology, patterns, and mechanisms of pediatric trauma : a review of 12, 508 patients. *European Journal of Trauma and Emergency Surgery*. [Online] 49 (1), 451–459. Available from: doi:10.1007/s00068-022-02088-6.
- Dewar, A. (2022) Disseminated intravascular coagulation for paediatricians: the whats, whys and hows. *Paediatrics and Child Health (United Kingdom)*. [Online] 32 (11), 433–440. Available from: doi:10.1016/j.paed.2022.08.005.
- DiMaio, V.J.M. & Molina, K.D. (2021) *DiMaio's forensic pathology*. (3rd edition). [Online]. New York, C.R.C. Press. Available from: doi:10.4324/9780429318764.
- Hettiaratchy, S. & Dziewulski, P. (2004) A.B.C. of burns introduction. *BMJ*. [Online] 328(1366–1368). Available from: doi:10.1136/bmj.328.7452.1366 [Accessed: 4 June 2022].
- Iba, T. & Levy, J.H. (2020) Sepsis-induced Coagulopathy and Disseminated Intravascular Coagulation. *Anesthesiology*. [Online] (5), 1238–1245. Available from: doi:10.1097/ALN.0000000000003122.
- Lucas, S. (2007) The autopsy pathology of sepsis-related death. *Current Diagnostic Pathology*. [Online] 13 (5), 375–388. Available from: doi:10.1016/j.cdip.2007.06.001.
- Marik, P.E. & Taeb, A.M. (2017) SIRS, qSOFA and new sepsis definition. *Journal of Thoracic Disease*. [Online] 9 (4), 943–945. Available from: doi:10.21037/jtd.2017.03.125.
- Mitra, B., Wasiak, J., Cameron, P.A., O'Reilly, G., et al. (2013) Early coagulopathy of significant burns. *Injury*. [Online] 44 (1). Available from: doi:10.1016/j.injury.2012.05.010.
- Moore, R.A., Waheed, A. & Burns, B. (2022) *Rule of Nines*. [Online]. Available from: <https://www.ncbi.nlm.nih.gov/books/NBK513287/?report=printable>.

- Putra, I.M.P. (2018) Pendekatan Sepsis dengan Skor SOFA. *CDK Journal*. 45 (8), 606–609.
- Saukko, P. & Knight, B. (2016) *Forensic Pathology 4th ed.* (4th edition). New York, C.R.C. Press.
- Setiawan, D. (2015) KPAI: *Pelaku Kekerasan Terhadap Anak Tiap Tahun Meningkat*. [Online]. 2015. Komisi Perlindungan Anak Indonesia. Available from: <https://www.kpai.go.id/publikasi/kpai-pelaku-kekerasan-terhadap-anak-tiap-tahun-meningkat> [Accessed: 3 March 2023].
- Singh, B., Hanson, A.C., Alhurani, R., Wang, S., et al. (2013) Trends in the incidence and outcomes of disseminated intravascular coagulation in critically ill patients (2004-2010): A population-based study. *Chest*. [Online] 143 (5). Available from: doi:10.1378/chest.12-2112.
- Takemitsu, T., Wada, H., Hatada, T., Ohmori, Y., et al. (2011) Prospective evaluation of three different diagnostic criteria for disseminated intravascular coagulation. *Thrombosis and Haemostasis*. [Online] 105 (1). Available from: doi:10.1160/TH10-05-0293.
- Taylor Jr., F.B., Toh, C.-H., Hooth W. Keith, Wada, H., et al. (2001) Scientific and standardization committee communications: towards a definition, clinical and laboratory criteria, and a scoring system for disseminated intravascular coagulation. *ISTH Website*.
- Thachil, J. (2016) Disseminated intravascular coagulation: a practical approach. *Anesthesiology*. [Online]. 125 (1). Available from: doi:10.1097/ALN.0000000000001123.
- Wada, H., Matsumoto, T. & Hatada, T. (2012) Diagnostic criteria and laboratory tests for disseminated intravascular coagulation. *Expert Review of Hematology*. [Online]. 5 (6). Available from: doi:10.1586/ehm.12.57.
- Wada, H., Thachil, J., di Nisio, M., Kurosawa, S., et al. (2013) Harmonized guidance for disseminated intravascular coagulation from the international society on thrombosis and haemostasis and the current status of anticoagulant therapy in japan: a rebuttal. *Journal of International Society on Thrombosis and Haemostasis*. [Online] 11 (11), 2078–2079. Available from: doi:10.1111/jth.12366.
- Wiegele, M., Schaden, E., Koch, S., Bauer, D., et al. (2019) Thrombin generation in patients with severe thermal injury. *Burns*. [Online] 45 (1). Available from: doi:10.1016/j.burns.2018.09.020.
- Zhang, L., Labib, A.M. & Hughes, P.G. (2022) *Escharotomy*. [Online]. Available from: <https://www.ncbi.nlm.nih.gov/books/NBK482120/?report=printable>.
- Zhang, T. Ning, Ba, T., Li, F., Chen, Q., et al. (2022) Coagulation dysfunction of severe burn patients: a potential cause of death. *Burns*. [Online] Available from: doi:10.1016/j.burns.2022.05.003.